

## OCT

Optical coherence tomography (OCT) arose from research done in the 1980s, which suggested that nerve fiber loss precedes visual field loss in glaucoma. This research led to a device capable of *in vivo* measurements of the thickness of the nerve fiber with hopes of diagnosing glaucoma earlier than visual field testing. One of the earliest devices was the GDx machine. At Newport Eye Center, we were 1 of 2 sites in California (with only 24 in the entire USA) in 1996 with this new GDx technology. At that time, it was somewhat experimental. Now, 20 years later, this technology has evolved into a device that can display optic nerve fiber and retinal detail greater than that which can be seen with the naked eye. OCT is no longer experimental but the standard of care.

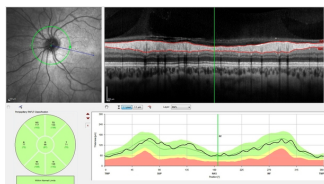
At Newport Eye Center, we offer the latest OCT technology, the “Spectralis”, made by Heidelberg Engineering. This OCT unit scans at 84,000 images/sec making it one of the most sensitive in the world (or out of this world, as the same unit is used on the Space Station). Newport Eye Center has a reputation for having the latest technologies for diagnosing eye disease.

The Spectralis uses a safe, low-powered, infrared laser to image the front to the back of the eye.

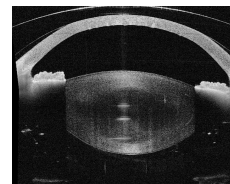


*Heidelberg OCT*

The OCT glaucoma test can display data showing how an individual's nerve fiber thickness compares to a normative database. The Spectralis also has eye tracking, meaning that it can image faster than other devices as well as scanning the same location at subsequent visits. This in turn means that we can precisely determine if the thicknesses are changing at any given location over time (trend analysis). Such information allows us to accurately monitor glaucoma.

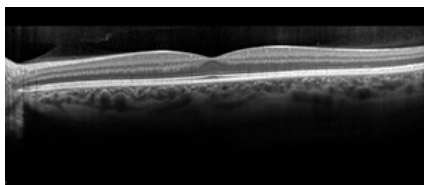


*Glaucoma scan – normal*

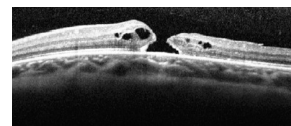


*Anterior segment (front of eye)*

Additionally, the Spectralis can examine in great detail various retinal layers of the macular area (the center vision area of the retina). Such tests can non-invasively reveal macular degeneration, macular edema, macular holes or other pathologies of the macula and retina.



*Normal macula*



*Macular hole*